

# THE OUTCOME OF TOTAL REVERSE SHOULDER ARTHROPLASTY FOR AVASCULAR NECROSIS OF THE HUMERAL HEAD AFTER OPEN REDUCTION AND INTERNAL FIXATION OF THE PROXIMAL HUMERUS: A CASE REPORT

Benedictus Anindita Satmoko<sup>1</sup>, Tabita Prajasari<sup>2\*</sup>

<sup>1</sup>Faculty of Medicine, Gadjah Mada University, Yogyakarta, Indonesia

<sup>2</sup>Orthopedic and Traumatology Department, Faculty of Medicine, Universitas Airlangga/Dr. Soetomo, General Hospital, Surabaya, Indonesia

## ABSTRACT

**Background:** The reverse total shoulder arthroplasty (RTSA) as a salvage procedure in avascular necrosis of the humeral head (AVNHH) after open reduction internal fixation (ORIF) becomes a challenging management of proximal humerus fracture (PHF). However, the functional outcomes and complication managements are still debatable. This report aims to provide the outcomes of RSTA as a salvage procedure on AVNHH post internal fixation.

**Case report:** A 68-year-old man was admitted to the orthopaedic outpatient clinic with shoulder pain and limitations doing daily activities such as combing his hair, putting on clothes, and raising his right hand up. He has a history of ORIF of the proximal humerus caused by PHF two years earlier. The clinical examination showed no swelling in the right shoulder with

a past operation scar on the anterior of the shoulder. We observed a slight bulging in the tip of the shoulder during shoulder abduction. The radiological examination showed a loss of fixation of the head of the humerus with degenerated humeral head. The patient underwent RTSA under general anaesthesia. Post-operative evaluation 2 years after surgery showed acceptable results.

**Conclusions:** A thorough functional evaluation after the ORIF procedure in PHF with high potential vascular injury should be done continuously in order to avoid avascular necrosis complications and to determine the decision of RTSA as a salvage procedure.

**Keywords:** avascular necrosis, proximal humeral head, reverse total shoulder arthroplasty, post-internal fixation complication, case report.

---

### Corresponding author:

Tabita Prajasari  
Orthopaedic and Traumatology Department,  
Faculty of Medicine, Airlangga University/Dr. Soetomo General Hospital  
Surabaya, Indonesia  
tabitaprajasari@gmail.com

## INTRODUCTION

The proximal humeral fractures (PHF), the most frequent adult and elderly fractures (>64 years old), have increased the incidence and severity since 2009 and they will triple by the year 2030.<sup>1–3</sup> They represent about 5.7% of all fracture cases that the PHF account for 50% of all humerus fractures.<sup>4,5</sup> These fractures are more susceptible in elderly women and are three times more common than in men. Most of these fractures are related to osteoporosis. The populations older than 60 years old made up more than 70% of patients with PHF.<sup>6,7</sup> As the risk of a PHF with associated bone fragility or risk of fall increases, the tendency of patient expectations on PHF treated by operative means is increasing.<sup>8,9</sup>

Although most PHFs are stable and managed by non-surgery treatment, the displaced and unstable fracture patterns comprise 15% to 20% of all cases and may affect the vascular supply of the humeral head.<sup>10,11</sup> The operative management choice is primarily considered for this case, yet the acute treatment of unstable with vascular disruption is challenging, time-consuming, and frequently controversial.<sup>12</sup> Current treatments include osteosynthesis using proximal humeral nails and plates, tension band wiring, percutaneous or minimally invasive techniques, such as pinning, intramedullary flexible nails, screw osteosynthesis, hemiarthroplasty, and reverse total shoulder arthroplasty (RTSA). Anatomical reduction and stable fixation became the main objective of surgical treatment because the unreduced or poorly reduced fractures with varus angulation of the humeral medial hinge can be serious problems leading to post-operative failure.<sup>13,14</sup>

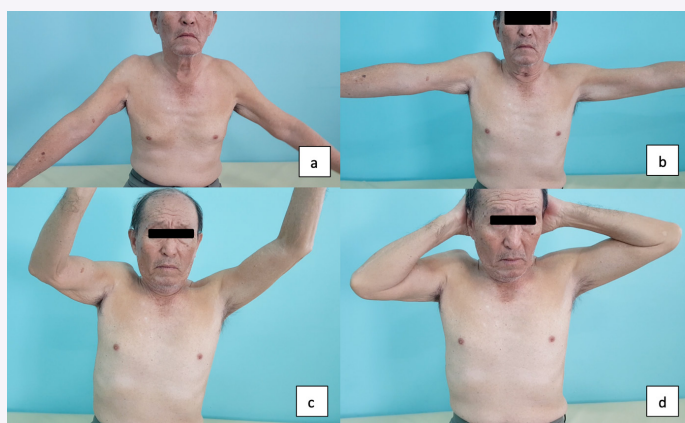The treatment of complex fracture patterns such as displaced three- or four-part PHF presents its own challenges. A range of surgical interventions are available for the treatment of complex PHF, including open reduction and internal fixation (ORIF) and arthroplasty/joint replacement either hemiarthroplasty (HA), anatomic total shoulder arthroplasty (TSA), or RTSA.<sup>15,16</sup> However, The

modern plates help to minimize post-operative complications by considering the medial calcar/medial hinge restoration, metaphyseal buttressing, and anatomic reduction of the tuberosities.<sup>17–20</sup> Use of proximal humeral locking plates, which are indicated for managing displaced two, three-, and four-part PHFs provide maximum stabilization by minimizing the peak stresses at the bone-implant interface.<sup>20,21</sup> Locking plates provide biomechanical strength and stability for restoring and fixing a fracture, especially for valgus-impacted fractures. However, the overall clinical benefit of locking plates for PHF fixation is controversial, both in their ability to treat complex PHF and in the predictability of patient outcomes. Additionally, complication rates associated with locking plate technologies can be unacceptably high such as osteonecrosis of the humeral head, fixation failure, infection, stiffness, and impingement. Some complications, such as screw penetration and implant breakage, seem unique to the implant.<sup>20–23</sup> The preliminary studies show that RTSA is considered as a salvage procedure for failed ORIF of PHF by addressing glenoid bone destruction and compensating for muscle imbalance.<sup>24</sup> So that, this report aims to provide the outcomes of RTSA as a salvage procedure for avascular necrosis of the humeral head (AVNHH) post ORIF proximal humerus. This case report has been reported in line with the Surgical Case Report (SCARE) 2020 Criteria.<sup>25</sup>

## CASE PRESENTATION

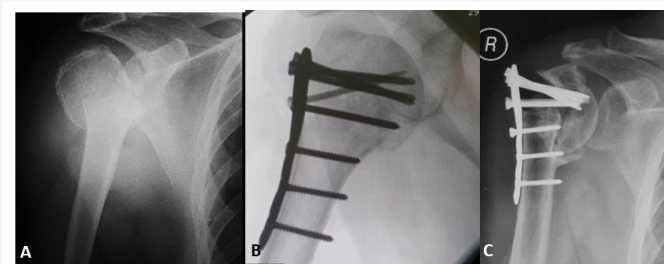
Mr. TH, a 68-years old man was admitted to the orthopaedic outpatient clinic of dr. Soetomo general hospital with pain in his right shoulder when he abducted and flexed his shoulder. The limitation occurred during those movements due to the pain. He had difficulties with daily routine activities such as combing his hair, putting on clothes, and raising his right hand up. The patient had a history of proximal humerus fracture on the affected shoulder 2 years ago which had been treated by open reduction and internal fixation with plate and screw. Following the previous surgery, no other traumatic events to the right shoulder.

A clinical examination revealed no swelling of the right shoulder, but there was a scar from a previous operation on the anterior aspect of the shoulder. We observed a bulging in the tip of the shoulder during shoulder abduction. No pain was observed on palpation. The range of movement (ROM) was limited on the right shoulder abduction and flexion. The patient experienced recognizable moderate pain with a visual analogue score (VAS) of 5 upon those movements. His right glenohumeral joint active ROM was 86° of abduction, 92° of forward flexion, 28° of external rotation and inferior gluteus level of internal rotation, respectively (Figure 1). The American Shoulder and Elbow Surgeon (ASES) Score was 32 and the Constant-Murley score (CMS) was 33.



**Figure 1.** The clinical examination showing the right shoulder limitation during active ROM due to the pain (b,c,d) and the shoulder tip bulging (a,b).

The radiological examination of the AP view of X-ray right shoulder showed a loss of fixation of the head of the humerus and calcar humeri with degenerated humeral head. The medial hinge angle was not in an acceptable position and a potential risk of further necrosis of the humeral head (Figure 2). The humeral head fragment is displaced inferiorly due to bone loss so that we can observe the bulging in the tip of the shoulder. From the radiological examination, we diagnosed the patient with AVNHH post ORIF proximal humerus. The RTSA was planned to manage the loss of fixation.



**Figure 2.** The initial Neer two-part surgical neck proximal humerus fracture (a) treated with ORIF (b). The radiological examination two years later showing the loss of fixation of the humeral head (c)

## Surgical Procedure

A general anesthetic was administered to the patient prior to elective surgery. The patient was positioned in a beach chair position with the affected upper extremity clearly exposed at the edge of the operating table so that the arm could be dislocated and extended freely. By using the elbow support, a slight angle of elbow flexion was achieved. An anterior deltopectoral approach was carried out by retraction of the cephalic vein laterally in the intermuscular plane between the pectoralis major and deltoid muscles in order to achieve an anterior deltopectoral approach. Between the long and short heads of the biceps muscles, a vertical incision of the clavipectoral fascia was made. Short head biceps and coracobrachialis muscles were mobilized medially to avoid the musculocutaneous nerve. The proximal humerus locking plate and locking screws were removed from the humerus, and the humeral head was excised.

For RTSA procedure, we used the Agilon® Reverse Shoulder Arthroplasty System (Implantcast GmbH, Germany). We performed the medullary cavity preparation with rigid drill 8 mm and reamed the canal with 110 mm depth using T-handle manually. The trial stem adapter of Agilonstem cemented M6\*N size 6/60 mm (implavit®, CoCrMo, ISO 5832-4) was inserted to the medullary canal. Following the mounting of the humeral alignment guide and cutting block to the trial stem adapter, we adjusted the retroversion by 8° and then determined the cutting height. For the metaphyseal component



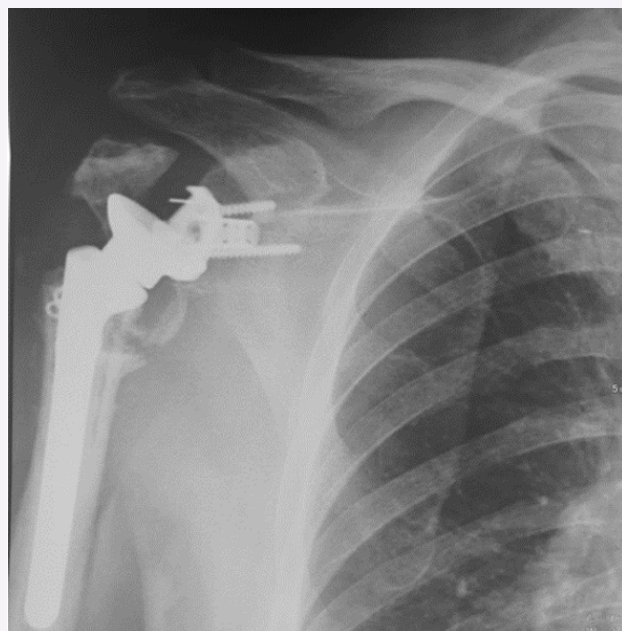
and bar screw, Agilon® metaphyseal component primary for trauma 135o 30 mm (Implatan®, TiAl6V4, ISO 5832-3) and Agilon® screw M6 22.5 mm (Implavit®, CoCrMo, ISO 5832-12 with TiN coating) was used, respectively.

The cutting height and retroversion were determined according to the implant used. The cutting block bone was fixed with fixation pins at a middle pin level. Following the removal of the alignment guide and trial intramedullary instruments, we added a third pin from cranial to caudal on the cutting block to improve stability. Having removed the head earlier, the purpose of this step was to trim the uneven edge of the humeral neck using a blade saw of 1.47 mm. The correct cap size and height were determined by measuring the resected head. Agilon® cap inverse 32 mm size S (Implatan®, TiAl6V4, ISO 5832-3 with TiN coating) and Agilon® PE-glenosphere size 2 32 mm eccentric (UHMWPE, ISO 5834-2) were utilized.

The trial stem was then inserted to the appropriate depth and the bone was cut to fit the metaphyseal component by using a box chisel. During glenoid preparation, the protection plate was placed upon the resected bone surface to ensure that the chisel had been retroverted by using the modular retroversion instrument. With 20 mm and 24 mm cancellous screws, we placed Agilon® glenoid baseplate cementless size 2 short (cpTi, ISO 5832-2-with HA coating) on the glenoid. The trial glenosphere was screwed to the glenoid base. To assess shoulder ROM, the trial inverse cap was used. After the shoulder stability check, all trial instruments were removed and the implant stem and metaphyseal component assembled.

Intramedullary plugs were inserted and bone cement was applied to the intramedullary canal. In the modular retroversion instrument set at 8o, the collar of the implant was adjusted until it rested on the resected bone surface. The PE-glenosphere was attached to the glenoid base using a head impactor to secure it. Through the use of a cap impactor, the inverse cap is

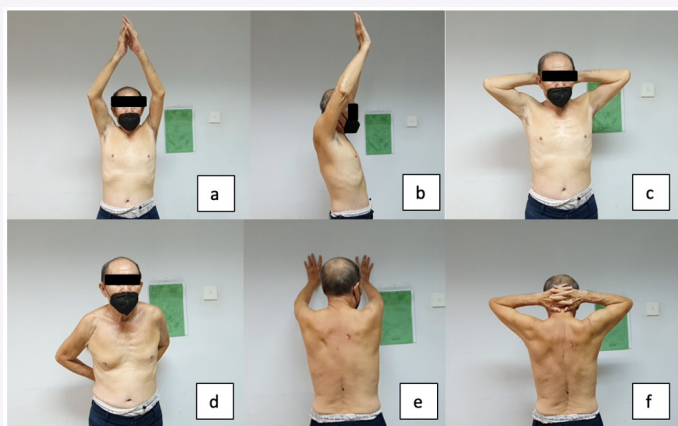
connected to the stem of the metaphyseal component (Figure 3). In addition, we performed the last stability test to ensure that the rotator cuff muscles were not reconstructed using RTSA technique. No complications were observed after surgery. An arm sling was worn by the patient immediately following surgery to provide support for his shoulder and to allow him to rest it.



**Figure 3.** The post-operative shoulder anteroposterior X-ray shows the humeral head and glenoid cavity have been replaced by the prosthesis in the appropriate anatomical position.

## Post-operative

Active-progressive and active-assisted ROM exercises of the shoulder joint were started as the post-operative pain was amenable. Post-operative evaluation was done 2 years after surgery to assess clinical results. The bulging of the tip shoulder disappeared. Right glenohumeral joint active ROM was 154o of abduction, 158o of forward flexion, and L3 level of internal rotation, 58o of external rotation, respectively. The VAS point score was 0 with the ASES score of 97 and the CMS of 94. The patient had full recovery of shoulder function and he can do daily routine activities without any discomfort as shown in figure 4.



**Figure 4.** Post RTSA functional outcomes. (a) abduction, (b) forward flexion, (c) external rotation, (d) internal rotation, (e) 90o flexion, (f) overhead movement

## DISCUSSION

AVNHH is associated with a complex pattern of PHFs, the posteromedial metaphyseal extension, residual medial hinge integrity, humeral head rotation, greater tuberosity dislocation over 8-10 mm, humeral head split fractures, and amount of fracture fragments. Medial calcar integrity becomes the main critical aspect influencing the humeral head blood supply.<sup>26</sup> The pre-operative factors and intra-operative factors should be analyzed carefully, particularly the combination of short medial metaphyseal extension and medial hinge disruption which are the most significant factor for this complication.<sup>27</sup> The failure of osteosynthesis depends on how severe medial hinge fragmentation is. Additionally, a multi-fragmentary fracture should be carefully treated so that the preservation of vascular supply can be maintained and devascularization can be avoided.<sup>28</sup> The other literature stated that between 3% to 37%, the post-traumatic osteonecrosis could happen, accordingly, the understanding of potential risk factors for humeral head osteonecrosis must be the priority of the treatment plan. For instance, the risk factors for humeral head osteonecrosis come into three groups of facts: establishing the role of anterior and posterior circumflex humeral arteries related to humeral head vascularization, detecting predictive X-ray signs for AVNHH, establishing the possibility for humeral head revascularisation using sparing surgical technique, anatomical reduction, and stable fixation. The anatomical reduction

and stable fixation allow revascularization and osteogenesis.<sup>28,29</sup> The prompt fracture reduction surgery yields the post-operative avascular necrosis (AVN) incidence reduction. However, the patient undergoing ORIF surgical technique is susceptible to AVNHH.<sup>8,30</sup> ORIF with osteosynthesis plate is a surgical strategy applied to those with displaced two or three-part humeral fractures. The objectives of the surgery are to achieve adequate reduction and fixation and optimize post-operative function. The deltopectoral approach which can limit exposure to the lateral and posterior aspects of the proximal humerus is an attractive option to achieve wide fracture visualization and reduction.<sup>31</sup>

In this report, the patient had an accident history and sustained a PHF, specifically with a significant displacement of the surgical neck. The thorough history taking of past diseases revealed no history of any disease relating to the risk factor of AVNHH. Robinson et al. reported that the risk factors like alcohol ingestion, age, and time to surgery had no influence on the fractures. Smoking was found a significant association with the AVNHH rate.<sup>8</sup> Archer et al. reported that time to surgery whether less than or greater than 72 h and patient age did not correlate with the development of AVN after PHF, while the number of fracture fragments and the complexity did correlate with that fracture complication.<sup>32</sup> The most possible risk factor of AVN following ORIF plating was the disruption of humeral head vascularization due to the surgical neck significant displacement in which most of the vital vessels of the humeral head are around that structure. Based on the anatomical structure, the PCHA is the most possible disrupted vessel as we observed the posterior displacement of the surgical neck on the first trauma radiological examination of the patient. The use of locking plates in ORIF procedures has been implicated in complications such as malreduction, screw cut-out, malunion, non-union, avascular necrosis, and infection.<sup>33</sup> The present meta-analysis suggested that the plate fixation in PHF management had a significantly higher risk of AVN than conservative treatment.<sup>34</sup> We can exclude the risk of AVNHH from the ORIF procedure in this patient because the medial hinge of the proximal humerus had perfectly reduced and the screw was in the

acceptable position. However, the potential risk of AVNHH from the mechanism of injury, delay of surgical procedure and the extended soft tissue injury which could potentially altered the humeral head vascularization in this patient should be considered should be considered. The decision to manage with alternative procedure RTSA should be considered in the first place.

Based on systematic review and meta-analysis conducted by Suroto et al., they suggested to manage patients aged over 64 years old who sustained a three- or four-part PHF. With the RSTA, forward flexion and CMS were improved, abduction was equal, external rotation was reduced, and revision surgeries were fewer.<sup>16</sup> Emilio et al. reported that patients with failed proximal humerus locking plate fixation who were revised to reverse shoulder arthroplasty (RSA) obtained marginally lower functional scores and higher complication rates than those with primary RSA.<sup>35</sup> However, most complications were manageable so the final outcome was not affected. RTSA has been regarded as a reliable salvage procedure for failed operative treatment of complex fractures of the PHF in elderly patients. This procedure can manage the glenoid bone destruction and compensate for muscle imbalance so that it has been considered for salvage of failed ORIF of PHF and allowed promising results in preliminary studies.<sup>36,37</sup> Although Kristensen et al. reported that the substantial risk of revision and low outcome of a shoulder arthroplasty after failed osteosynthesis for PHF was increased,<sup>38</sup> this patient who underwent RTSA as a salvage procedure due to loss of fixation following AVNHH had a good outcome. We agree with Hussey et al. that improvement in outcomes and pain can be expected by cautiously major complication management after surgery.<sup>24</sup> In recent meta-analysis, the use of RTSA implant with neck-shaft angle 135o provided better abduction and tuberosity healing than that of 145o and 155o which this report also provided acceptable result.<sup>16,39</sup> The limitation of this report is the lack of clinical pictures at the time of the first trauma event that may depict the severity of upper extremity deformity and no CT-scan image evaluation prior to RSTA.

## CONCLUSION

The management of PHF by internal fixation must consider not only the anatomical reduction of the medial hinge of proximal head humerus but also the potential risk factors of vascular disruption and fracture displacement which can lead to avascular necrosis complications, such as the degrees of injuries and the potential vascular disruption during ORIF procedure. A thorough functional evaluation follow-up after the ORIF procedure on PHF should be done in order to determine the decision of RTSA as a salvage procedure.

## ACKNOWLEDGEMENTS

We would like to express our deep gratitude to Dr.dr. Heri Suroto, Suroto, SpOT(K), FICS, our research supervisor and teacher, for his patient guidance, enthusiastic encouragement and useful critiques of this case report.

## DECLARATIONS

*Funding: This case report received no specific grant from any funding agency in the public, or non-profit sector*

*Conflict of interest: The authors have no conflicts of interest to disclose*

*Ethical approval: Ethical approval was waived by the authors institution.*

*Patient consent: Written informed consent was obtained from the patient for publication of this case report and accompanying images. A copy of the written consent is available for review by the Editor-in-Chief of this journal on request.*

*Patient perspective: The pain in the right shoulder was so devastating that I could not perform daily activity. However, the physician's surgical technique and rehabilitation support me until I could do daily activities free from pain.*



## REFERENCE

1. Court-Brown CM, McQueen MM, Garg A. The epidemiology and outcome of proximal humeral fractures. *J Orthop Trauma*. 2000;14(2):118. doi:10.1097/00005131-200002000-00013
2. Launonen AP, Lepola V, Saranko A, Flinkkilä T, Laitinen M, Mattila VM. Epidemiology of proximal humerus fractures. *Arch Osteoporos*. 2015;10(1):1-5. doi:10.1007/s11657-015-0209-4
3. Palvanen M, Kannus P, Niemi S, Parkkari J. Update in the epidemiology of proximal humeral fractures. *Clin Orthop Relat Res*. 2006;442(442):87-92. doi:10.1097/01.blo.0000194672.79634.78
4. Kim SH, Szabo RM, Marder RA, Marder A. Epidemiology of Humerus Fractures in the United States : Nationwide Emergency Department Sample , 2008. 2012;64(3):407-414. doi:10.1002/acr.21563
5. Roux A, Decroocq L, Batti S El, et al. Epidemiology of proximal humerus fractures managed in a trauma center. *Orthop Traumatol Surg Res*. 2012;98(6):715-719. doi:10.1016/j.otsr.2012.05.013
6. Verde L La, Franceshetti E, Familiari F, Franceschi F. Complications of ORIF in Proximal Humeral Fractures. *Shoulder Arthroplast*. Published online 2020:173.
7. Christiano A, Christian P, Sanjit K, Kenneth E. Functional outcome after PHF fixation: Risk factors. 2017;83(212):1-7.
8. Robinson CM, Stirling PHC, Goudie EB, Macdonald DJ, Strelzow JA. Complications and Long-Term Outcomes of Open Reduction and Plate Fixation of Proximal Humeral Fractures. *J Bone Jt Surg - Am Vol*. 2019;101(23):2129-2139. doi:10.2106/JBJS.19.00595
9. Lee SH, Dargent-Molina P, Bréart G. Risk factors for fractures of the proximal humerus: Results from the EPIDOS prospective study. *J Bone Miner Res*. 2002;17(5):817-825. doi:10.1359/jbmr.2002.17.5.817
10. Björkenheim JM, Pajarinen J, Savolainen V. Internal fixation of proximal humeral fractures with a locking compression plate: A retrospective evaluation of 72 patients followed for a minimum of 1 year. *Acta Orthop Scand*. 2004;75(6):741-745. doi:10.1080/00016470410004120
11. Gerber C, Werner CML, Vienne P. Internal fixation of complex fractures of the proximal humerus. *J Bone Jt Surg - Ser B*. 2004;86(6):848-855. doi:10.1302/0301-620X.86B6.14577
12. Relvas Silva M, Linhares D, Leite MJ, et al. Proximal humerus fractures: epidemiology and trends in surgical management of hospital-admitted patients in Portugal. *JSES Int*. 2022;6(3):380-384. doi:10.1016/j.jseint.2021.12.003
13. Aggarwal S, Bali K, Dhillon MS, Kumar V, Mootha AK. Displaced proximal humeral fractures: An Indian experience with locking plates. *J Orthop Surg Res*. 2010;5(1):1-8. doi:10.1186/1749-799X-5-60
14. Robinson CM, Amin AK, Godley KC, Murray IR, White TO. Modern perspectives of open reduction and plate fixation of proximal humerus fractures. *J Orthop Trauma*. 2011;25(10):618-629. doi:10.1097/BOT.0b013e31821c0a2f
15. Dey Hazra RO, Blach RM, Ellwein A, Katthagen JC, Lill H, Jensen G. Latest Trends in the Current Treatment of Proximal Humeral Fractures-an Analysis of 1162 Cases at a Level-1 Trauma Centre with a Special Focus on Shoulder Surgery. *Z Orthop Unfall*. 2022;160(3):287-298. doi:10.1055/a-1333-3951
16. Suroto H, Vega B De, Deapsari F, Prajasari T, Wibowo PA, Samijo SK. Reverse total shoulder arthroplasty (RTSA) versus open reduction and internal fixation (ORIF) for displaced three-part or four-part proximal humeral fractures: a systematic review and meta-analysis. *EFORT Open Rev*. 2021;6(10):941-955. doi:10.1302/2058-5241.6.210049
17. Rose PS, Adams CR, Torchia ME, Jacofsky DJ, Haidukewych GG, Steinmann SP. Locking plate fixation for proximal humeral fractures: Initial results with a new implant. *J Shoulder Elb Surg*. 2007;16(2):202-207. doi:10.1016/j.jse.2006.06.006

18. Weinstein DM, Bratton DR, Ciccone WJ, Elias JJ. Locking plates improve torsional resistance in the stabilization of three-part proximal humeral fractures. *J Shoulder Elb Surg.* 2006;15(2):239-243. doi:10.1016/j.jse.2005.08.006
19. Gardner MJ, Weil Y, Barker JU, Kelly BT, Helfet DL, Lorich DG. The importance of medial support in locked plating of proximal humerus fractures. *J Orthop Trauma.* 2007;21(3):185-191. doi:10.1097/BOT.0b013e3180333094
20. Macy J. Fixation of a Proximal Humeral Fracture Using a Novel Intramedullary Cage Construct following a Failed Conservative Treatment. *Case Rep Orthop.* 2017;2017:1-4. doi:10.1155/2017/4347161
21. Ong CC, Kwon YW, Walsh M, Davidovitch R, Zuckerman JD, Egol K. Outcomes of Open Reduction and Internal Fixation of Proximal Humeral Fractures Managed With Locking Plates. *Am J Orthop.* 2012;41(9):407-412.
22. Koukakis A, Apostolou CD, Taneja T, Korres DS, Amini A. Fixation of proximal humerus fractures using the PHILOS plate: Early experience. *Clin Orthop Relat Res.* 2006;442(442):115-120. doi:10.1097/01.blo.0000194678.87258.6e
23. Strohm PC, Helwig P, Konrad G, Südkamp NP. Locking plates in proximal humerus fractures. *Acta Chir Orthop Traumatol Cech.* 2007;74(6):410-415.
24. Hussey MM, Hussey SE, Mighell MA. Reverse shoulder arthroplasty as a salvage procedure after Failed internal fixation of fractures of the proximal humerus: Outcomes and complications. *Bone Jt J.* 2015;97-B(7):967-972. doi:10.1302/0301-620X.97B7.35713
25. Agha RA, Franchi T, Sohrabi C, et al. The SCARE 2020 Guideline: Updating Consensus Surgical CAse REport (SCARE) Guidelines. *Int J Surg.* 2020;84:226-230. doi:10.1016/j.ijsu.2020.10.034
26. Maresca A, Senesi L, Cerbasi S, Pascarella R. Complications of proximal humeral fractures. *Lo Scalpello - Otodi Educ.* 2021;35(1):20-26. doi:10.36149/0390-5276-201
27. Fourrier P, Martini M. Post-traumatic avascular necrosis of the humeral head. *Int Orthop.* 1977;1(3):187-190. doi:10.1007/BF00266336
28. Totev K, Dimitrov G, Toteva L, Todorov S, Lungarov S. Risk Factors for Humeral Head Osteonecrosis in Patients With Proximal Humeral Fractures Treated Operatively. *J IMAB - Annu Proceeding (Scientific Pap.* 2021;27(4):4072-4076. doi:10.5272/jimab.2021274.4072
29. Patel S, Colaco HB, Elvey ME, Lee MH. Post-traumatic osteonecrosis of the proximal humerus. *Injury.* 2015;46(10):1878-1884. doi:10.1016/j.injury.2015.06.026
30. Boesmueller S, Wech M, Gregori M, et al. Risk factors for humeral head necrosis and non-union after plating in proximal humeral fractures. *Injury.* 2016;47(2):350-355. doi:10.1016/j.injury.2015.10.001
31. Mohan K, Hintze JM, Morrissey D, Molony D. Incidence of avascular necrosis following biceps tenodesis during proximal humerus open reduction and internal fixation. *Acta Orthop Belg.* 2021;87(2):339-346. doi:10.52628/87.2.20
32. Archer LA, Furey A. Rate of avascular necrosis and time to surgery in proximal humerus fractures. *Musculoskelet Surg.* 2016;100(3):213-216. doi:10.1007/s12306-016-0425-0
33. Jost B, Spross C, Grehn H, Gerber C. Locking plate fixation of fractures of the proximal humerus: Analysis of complications, revision strategies and outcome. *J Shoulder Elb Surg.* 2013;22(4):542-549. doi:10.1016/j.jse.2012.06.008
34. Xu J, Zhang C, Wang T. Avascular necrosis in proximal humeral fractures in patients treated with operative fixation: A meta-analysis. *J Orthop Surg Res.* 2014;9(1):1-6. doi:10.1186/1749-799X-9-31
35. Sebastia-Forcada E, Lizaur-Utrilla A, Cebrian-Gomez R, Miralles-Muñoz FA, Lopez-Prats FA. Outcomes of Reverse Total Shoulder Arthroplasty for Proximal Humeral Fractures: Primary Arthroplasty Versus Secondary Arthroplasty after Failed Proximal Humeral Locking Plate Fixation. *J Orthop Trauma.* 2017;31(8):e236-e240. doi:10.1097/BOT.0000000000000858



36. Ernstbrunner L, Rahm S, Suter A, et al. Salvage reverse total shoulder arthroplasty for failed operative treatment of proximal humeral fractures in patients younger than 60 years: long-term results. *J Shoulder Elb Surg.* 2020;29(3):561-570. doi:10.1016/j.jse.2019.07.040
37. Grubhofer F, Wieser K, Meyer DC, Catanzaro S, Schürholz K, Gerber C. Reverse total shoulder arthroplasty for failed open reduction and internal fixation of fractures of the proximal humerus. *J Shoulder Elb Surg.* 2017;26(1):92-100. doi:10.1016/j.jse.2016.05.020
38. Kristensen MR, Rasmussen JV, Elmengaard B, Jensen SL, Olsen BS, Brorson S. High risk for revision after shoulder arthroplasty for failed osteosynthesis of proximal humeral fractures: A matched pair analysis of 285 cases from the Danish Shoulder Arthroplasty Registry. *Acta Orthop.* 2018;89(3):345-350. doi:10.1080/17453674.2018.1450207
39. O'Sullivan J, Lädermann A, Parsons BO, et al. A systematic review of tuberosity healing and outcomes following reverse shoulder arthroplasty for fracture according to humeral inclination of the prosthesis. *J Shoulder Elb Surg.* 2020;29(9):1938-1949. doi:10.1016/j.jse.2020.03.032